

ACHALASIA ACTION

www.achalasia-action.org

Uniting for a rare swallowing condition

Email: info@achalasia-action.org

Forum: <https://healthunlocked.com/achalasia-action>

ACHALASIA: PAIN RELIEF AND OTHER ISSUES

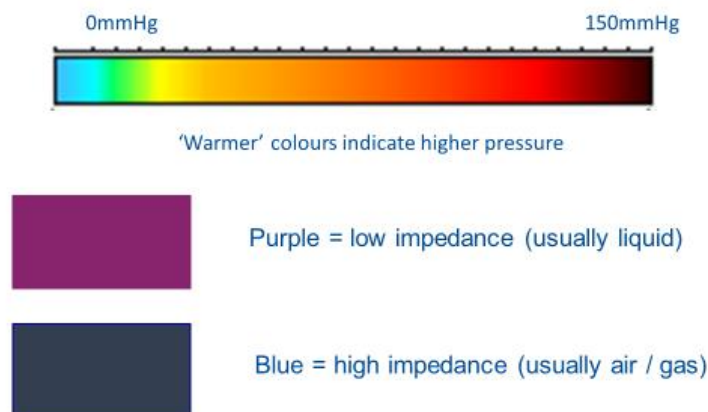
Via Zoom Tuesday 13 October 2020 at 5.30pm

With Majid Hashemi, Medical Chair ACAC; Anthony Hobson, Clinical Director Functional Gut Clinic, and Sach Kumar, Consultant Upper GI surgeon, Royal Marsden hospital. (60 participants).

Presentation by Anthony Hobson:

High resolution manometry and impedance has transformed the diagnostic process. It is the basis on which the details of your treatment are based. The tube is much thinner and less uncomfortable than before, with six pressure points being measured. The colour codes indicate to a professional the location of problems within the oesophagus as indicated by the pressure waves exerted by the muscles performing / not performing the swallowing function (peristalsis).

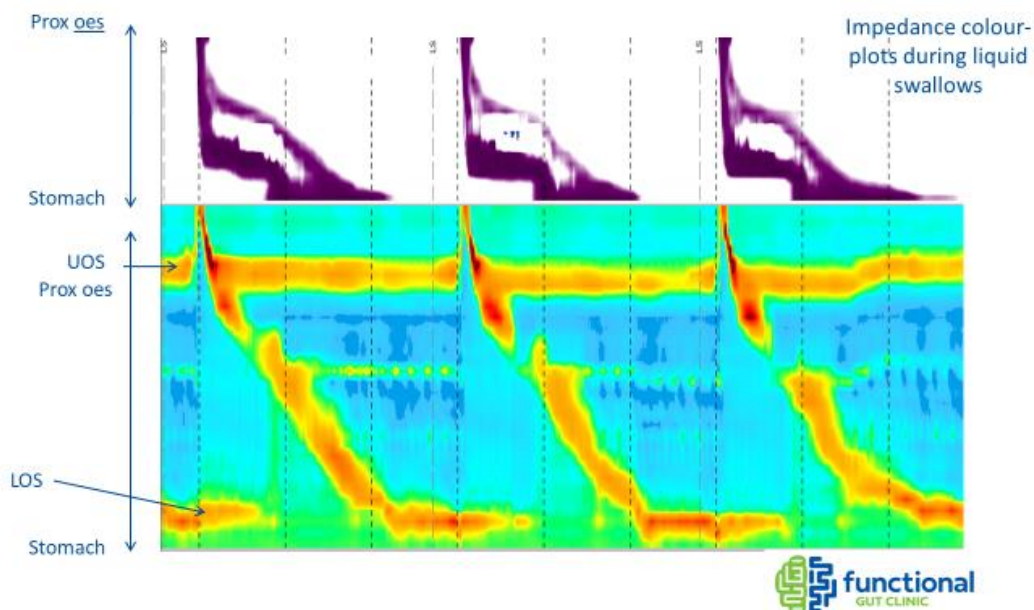
HRM and Impedance - decode



A *normal* oesophagus shows the liquid progressing down through the oesophagus, the top of the chart showing the top end of the oesophagus, and the time lapse indicated left to right across the chart:

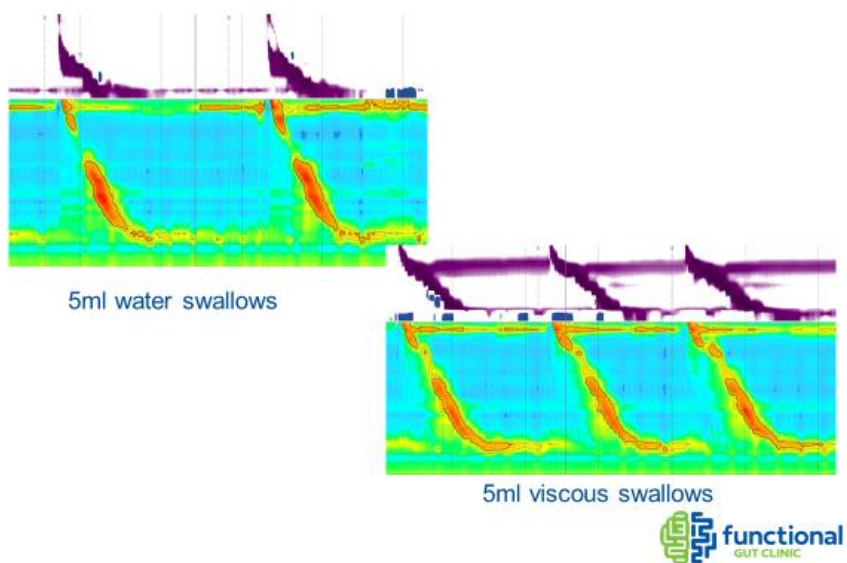
40 Orpington Road, Winchmore Hill, London, England N21 3PG
Charitable Incorporated Organisation registered in England & Wales no 1187367
Medical Chair & Trustee: **Majid Hashemi FRCS** Trustees: **Amanda Ladell, Alan Moss, Andrew Williams, Neil Ham, Silvia Davey, Gavin Nash, David Holden.**

High Resolution Oesophageal Manometry and Impedance – Normal Swallow and Bolus Clearance

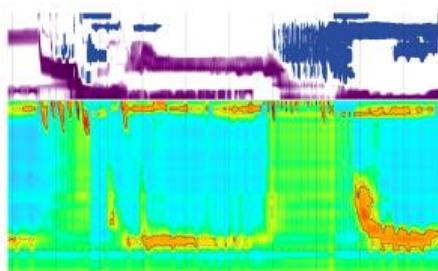


Take home message 1 - Impedance allows us to see the functional consequence of physiological events. Tests can illustrate 5ml *water* swallows, or how the system reacts to *more viscous* items that are swallowed. These can also involve 'challenge' swallows to give further information to improve the diagnosis, sometimes repeating swallowing at intervals, for investigating how the lower oesophageal sphincter works under pressure.

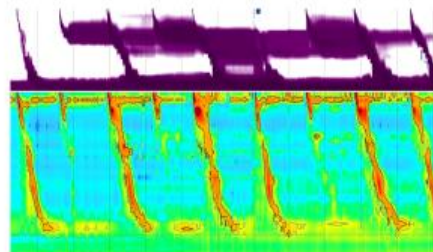
Designing your test



Designing your test



- 5x2ml multiple rapid swallows (Neural Function)
- 200ml rapid drink challenge (Outflow Obstruction)



- Solid swallows (individual swallows or meal)



The Chicago Classification of the types of Achalasia:

The findings of the manometry determine what type of achalasia is diagnosed, using the Chicago classification system (version 3, and version 4 with small variations expected soon) and resting pressure readings. This aims to standardise measurements and classifications to enable more consistent communication within the medical world:

	CCv3.0 with ten 5 mL single water swallows ⁶	CC-5 with standard soft-cooked rice test meal ⁷
Achalasia type 1	Mean IRP >15 mm Hg, 100% failed peristalsis (premature [spastic] contractions with DCI <450 mm Hg x s x cm are failed peristalsis)	≥2 swallows with IRP >25 mm Hg, ≤1 effective swallow, otherwise unchanged
Achalasia type 2	Mean IRP >15 mm Hg, no normal peristalsis, POP with ≥20% swallows	≥2 swallows with IRP >25 mm Hg, ≤1 effective swallow, otherwise unchanged
Achalasia type 3	Mean IRP >15 mm Hg, no normal peristalsis, premature (spastic) contractions with ≥20% wet swallows, may be mixed with POP	≥2 swallows with IRP >25 mm Hg, ≤1 effective swallow, otherwise unchanged
Oesophagogastric junction outflow obstruction	Mean IRP >15 mm Hg, not meeting criteria for achalasia	≥2 swallows with IRP >25 mm Hg, not meeting criteria for achalasia
Spasm	Normal mean IRP ≥20% premature contractions (distal latency <4-5 s)	≥2 swallows with distal latency <4-5 s
Hypercontractile motility (ie, jackhammer oesophagus)	≥2 oesophageal contractions with DCI >8000 mm Hg x s x cm (hypercontractility can involve or be localised to the oesophagogastric junction)	Unchanged
Absent peristalsis (ie, aperistalsis)	Normal mean IRP, 100% swallows with failed peristalsis, DCI <100 mm Hg x s x cm	≤1 swallow with IRP >25 mm Hg, ≤1 swallow not fulfilling criteria of failed peristalsis (DCI <100 mm Hg x s x cm)
Ineffective oesophageal motility (weak or fragmented peristalsis*)	Mean IRP <15 mm Hg and >50% contractions with DCI <450 mm Hg x s x cm or >5 cm breaks in the 20 mm Hg isobaric contour	≤1 swallow with IRP >25 mm Hg and >80% pharyngeal swallows associated with ineffective oesophageal contractions during solid test meal defined by DCI <1000 mm Hg x s x cm or >3 cm breaks in the 25 mm Hg isobaric contour
Hypertensive motility (ie, nutcracker oesophagus)†	Oesophageal contraction with mean DCI >5000 mm Hg x s x cm not meeting criteria for hypercontractile oesophagus	≥2 oesophageal contractions with DCI >5000 mm Hg x s x cm

CCv3.0= Chicago Classification v3.0. CC-5= Chicago Classification adapted for solids. IRP=integrated relaxation pressure. DCI=distal contractile integral. POP=panoesophageal pressurisation. * Definition of ineffective oesophageal motility in this study includes both weak and fragmented motility on the basis of evidence that these two conditions exist together, both have similar effects on bolus transport, and both have similar clinical presentation and outcome. †From Chicago Classification version 2 (diagnosis removed from version 3).

Achalasia Type 1 tends to involve longer term / chronic distension/ dilatation of the oesophagus that does not have so much / any muscle pressure.

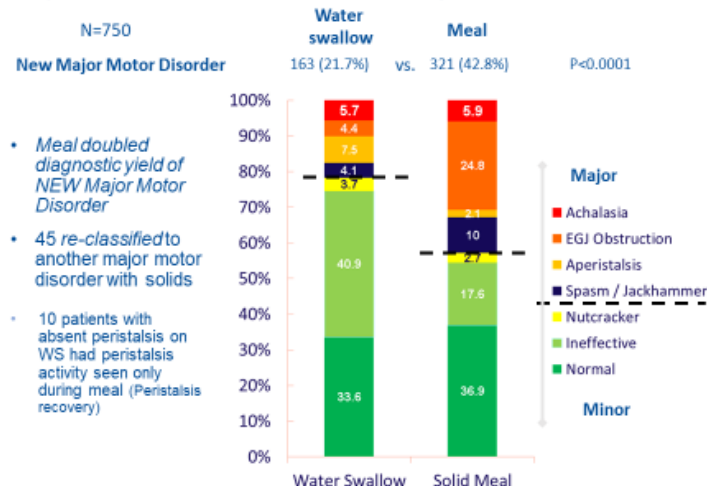
Type 2 can involve early onset achalasia when there is a poorly-relaxing lower oesophageal sphincter (LOS) whilst there is still some tone and pressure with the muscles but there is no peristalsis. In some ways this can be more straightforward to treat as it can be responsive to dilatation and myotomy.

Type 3 is a more complicated version of Type 2 when there tends to be quite a lot of spasms.

So Types 1 and 3 can be more complicated to treat than Type 2, but each case is individual.

Analysing patients having a meal rather than just swallowing water tends to show more cases of Oesophageal / Gastric junction obstruction arising from a variety of causes, rather than just achalasia. Picking these up and treating them early with dilatation can act to preserve their motility (ability to move food through the digestive system) before the oesophagus becomes exhausted. This can then prevent some cases from developing into severe achalasia-related conditions:

Major Motor Disorders in Single water vs. Meal

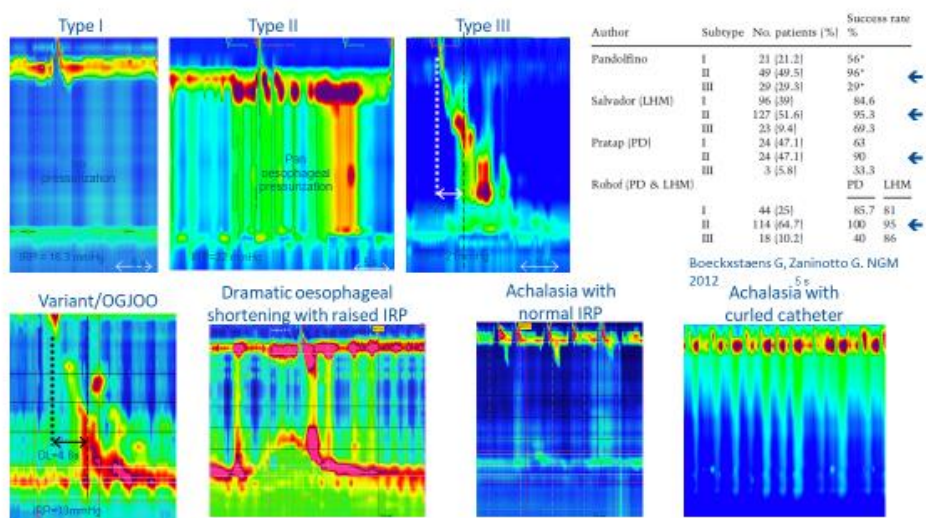


Ang et al 2017



In these charts (below) showing different types of achalasia, type 1 is indicated by the absence of pressure in the body of the oesophagus because it is dilated. Type 2 shows a non-relaxing LOS but with some pressurisation in the body of the oesophagus. Type 3 indicates spastic contractions and a non-relaxing LOS. A number of variants are also shown with integrated relaxation pressure (IRP), including when the oesophagus is 'shortened' which can be a cause of pain, including after a dilatation.

Possible Presentations of Achalasia



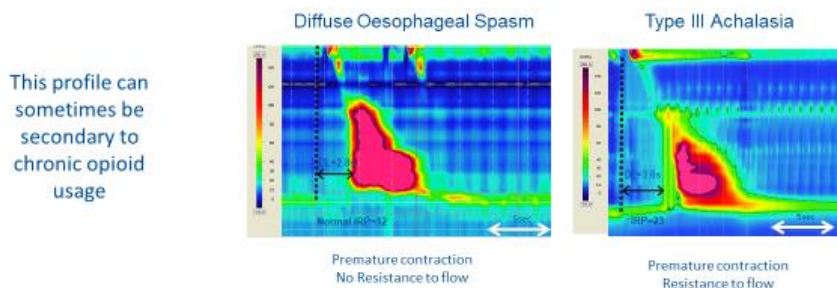
Slide courtesy of Rami Sweis



Some manometry profiles (below) can show the difference between diffuse oesophageal spasms and Type 3 achalasia according to whether the LOS relaxes or not. Chronic opioid usage can sometimes result in a form of constipation in the oesophagus as well as in the lower bowel, in which case a change in medication can help.

Careful analysis is needed to distinguish other conditions that can look like achalasia at first sight.

Diffuse Oesophageal Spasm (DL < 4.5s) vs. Type III Achalasia



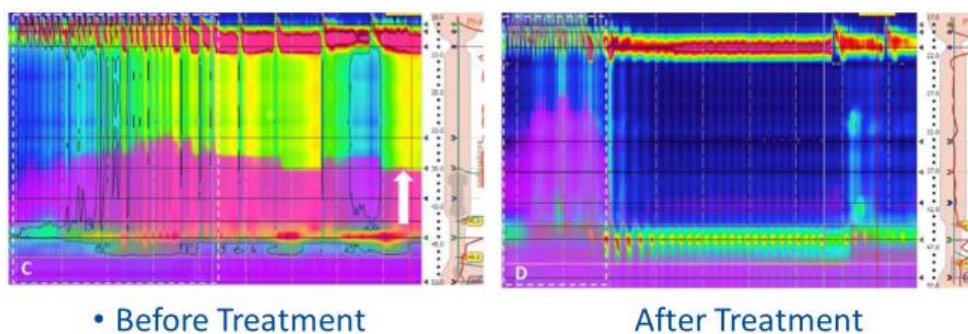
Roman, S., & Kahrlas, P. J. Current Opinion in Gastroenterology 2015.

Slide courtesy of Rami Sweis



A timed barium swallow can be measured with manometry and can show the effect before and afterwards to demonstrate how effective the treatment has been. In the example below, the barium is successfully clearing the oesophagus completely:

Rapid Drink Challenge - Bolus retention as a measure of treatment success



Cho et al. Am J. 2014



High resolution manometry has been very beneficial in guiding future treatment in the form of dilatation, myotomy or POEM and to provide evidence for follow-up studies.

QUESTIONS AND ANSWERS

What causes the chest pains?

Chest pains from the oesophagus (for example as experienced from an endoscopic dilatation), can be quite panic-inducing. The oesophagus itself does not have many nerves as such, but the spasms can continue to build up progressively and transmit pain to other parts of the body through the sections of the nerve system in the spinal cord that travel to the heart, arm or jaw and then to the autonomic nerve system that affects sweating, clamminess and palpitations. The effect can be ischaemic (affecting blood supply) and the muscles can start to run out of oxygen, making things worse.

Effective peristalsis relies on a good balance between different sorts of nerve receptor activity (excitatory and inhibitory) in the oesophagus that will control the muscles propelling the food into the stomach. Achalasia inevitably affects the number of these nerve receptors talking to each other and giving proper control of the muscles, and when achalasia becomes pernicious these nerve functions progressively deteriorate. Treatment, by dilatation for instance in Type 1 and 2 to remove the LOS obstruction, should remove the cause of most spasms because the oesophagus will then act as a tube where food moves through it by gravity.

With Type 3, it is more difficult because the spasm is itself likely to cause an obstruction as well as pain. In the past various medications have been tried (eg nifedipine, angina remedies, sub-lingual GTN) to try and relax things, but there has not really been an effective medication to combat the spasms. That is why ~~the~~ surgery aiming for a [laparoscopic](#) myotomy over a longer stretch of muscle, ~~and or~~ POEM, have been relatively more successful [than medical treatments](#). It does show

the importance of following up treatment with manometry to check that spasms have been dealt with as far as possible, and for manometry to replicate normal life eating situations by using tests that involve something more solid than water to test out the oesophagus properly.

The oesophagus naturally wants to empty itself so *spasms at night* can be a reflection of the nerve system dilating the oesophagus and trying to get rid of residual food (as if it is an angry oesophagus). It may also be affected by reflux at night when you are horizontal and stomach acid can flow 'upwards' into the oesophagus. Some medications can help with relaxation but it is difficult to analyse random spasms without a pattern if doctors cannot examine the patient when the spasms are actually occurring. There has not been much research into medication that might help. Some studies have apparently found that Viagra can sometimes help spasms because of an effect on blood flow.

Sometimes there is a randomness to symptoms. The body can get used to tolerating things. Sometimes the oesophagus becomes dilated, so this does create variations in pain. The oesophagus will be trying to clear itself 'against a blocked drainpipe'. There is a spectrum in achalasia and people may find that their symptoms change over time. Often there is a delay in diagnosis and this can contribute to variations in symptoms.

If there is a different type of pain after treatment compared to beforehand there should be some form of post-treatment assessment. Rib pain on the right hand side might feasibly be connected to surgical intervention, but is very unusual in achalasia. Pain can transfer to other locations through the nerve system as referred pain. It is important for different chest pains to be investigated as they may be caused by a problem other than achalasia.

Spasms are not experienced by all achalasia sufferers at all.

Early Intervention for swallowing problems

Before the most recent developments of high resolution manometry it was not possible to see the details of LOS obstruction very clearly, and therefore there was a reluctance to perform dilatation of the LOS. Now, a gentle dilatation has been shown sometimes to result in peristalsis being restored. Dysphagia (difficulty in swallowing) is an alarming symptom and it needs to be investigated, not least because there might be an obstruction of some form of potentially cancerous tumour, but it should not be the case that a patient is informed that cancer has been ruled out but that nothing more can be done. Botox has been used as a remedy, but it can tend to track back up the oesophagus and paralyse the parts of the oesophagus needed for peristalsis, so Anthony Hobson is reluctant to use it for early onset interventions.

Can achalasia change from one type to another?

Type 2 can more likely deteriorate into type 1 as the obstruction persists and the tone of the oesophagus worsens. It then loses both its shape and its remaining peristalsis and effectiveness. In some respects end stage achalasia is Type 1 when it will have reached its worst point. Type 3 might happen in early onset cases but this is uncertain. Type 3 can also deteriorate but it is really important to consider all the details of each individual case. Early intervention is key. Important that proper diagnostic tests and procedures are followed, not least to exclude other conditions, with good collaboration (work up) between gastroenterologists, surgeons and physiologists.

An Autoimmune Disease?

People have been trying to understand the causes of achalasia for many years, including considering insect bites and Chagas disease in South America, the effect of chronic reflux, a link with the herpes virus, an auto-immune response to something, or the reaction of the oesophagus to an outflow obstruction. Nobody has found the definitive answer yet as the cause is so poorly understood. There could be several different triggers.

Dental problems

Reflux and stagnant food can cause damage to tooth enamel as a side effect. Rather than being caused by achalasia directly.

Can achalasia cause forgetfulness?

Not known.

POEM (per oral oesophageal myotomy)

This discussion reflected the opinions of the medical experts attending. Might Sa1280 POEM, also O-POEM, as used in the USA become a standard treatment in the future? From a surgeon's point of view, POEM is predominantly undertaken by gastroenterologists, and there is not sufficient trial data to be reassured about the long term effects of the consequent reflux, or long term use of PPI medication that POEM would entail, whereas a surgeon would be able to undertake an anti-reflux operation ie fundoplication. The POEM v Heller's myotomy debate is ongoing. Surgeons can examine the result of a myotomy themselves with endoscopy. The specific POEM variation referred to in the question may relate to some form of anti-reflux provision, but there is insufficient information and data to make any judgement. POEM is still regarded as experimental in the UK. POEM and a myotomy both involve cutting of the same muscles, so one is not 'bigger' than the other, as both procedures involve a certain element of risk and they are both of about two hours' duration. The biggest potential problem is of very significant reflux with potential aspiration into the lungs, hoarseness, dental enamel problems, erosive oesophagitis and long term health issues, so it is not a matter of minor reflux that is simply inconvenient. PPI medication (eg Omeprazole, that switches off the production of stomach acid) is safe, but can have long term side effects so if there is an option of avoiding PPIs there is an advantage. Taking them for a year or so is no problem; but longer term use should be subject to regular review. It is important that doctors undertaking POEM should be very well trained in the procedures. There are conflicts of opinion and interest between gastroenterologists and surgeons in the USA about reflux issues. There are opinions advancing anti-reflux devices such as Stretta and TIF but these do not seem to work as well as the Linx magnetic bracelet. POEM can be effective at clearing the LOS obstruction, but it is important not to risk long term side effects that have to be treated in the future.

POEM can sometimes be effective at dealing with Type 3 achalasia and the need for longer cutting of muscles mid-way down the oesophagus, and it has been used by gastroenterologists in the USA like John Pandolfino for patients unable to come off long term opioids. In theory the same muscles are cut with both procedures, but POEM can operate higher towards the throat [although access very high up onto the oesophagus can also be achieved safely laparoscopically](#). Sometimes patients are referred for POEM when the location of the affected muscles are higher up, or when there is a technical reason for making access with an endoscope better for the patient [\(extremely rare that someone cannot be accessed laparoscopically\)](#). Recovery time from a laparoscopic myotomy is normally 24 – 48 hours before discharge from hospital. Both procedures may involve a certain level of manageable temporary pain or discomfort. There is not really a standard method of comparison between the two procedures. You really want a good work up (collaborative testing and diagnosis

by different specialists) and then an agreed definitive treatment as early as possible for the best chance of success. For any intervention on the oesophagus, the aim should be to intervene once and once only.

Diet

A question was asked about a teenage girl who has suffered from achalasia since the age of nine, had a long stay in hospital, a Heller's myotomy, surgery to undo the myotomy and then a POEM for whom the parents feel that it is a struggle to persuade her away from small amounts of sweet and greasy food rather than healthier eating options. It is important to recognise that having had swallowing problems for most of her life, then a number of specialists could justifiably become involved. This issue comes up quite often. There will be learned behaviours around eating, fears relating to food, issues around timing of eating and many different layers to the problem. A psychologist and/or specialist for dealing with food anxieties may be helpful. One person who had herself suffered as a teenager expressed the view that she had concentrated on high calorie food such as chocolate and crisps initially as that was the only food she was able to eat, and that gave her the best benefit for what was possible or easy to swallow. After some time she then developed a healthier eating regime after her achalasia improved.

There may well be some issues specific to young people and children with achalasia. Antje from the German Achalasia self-help group said that their younger achalasia sufferers varied a great deal, but that they often ate simply what they felt they could best tolerate. She was aware of one boy aged 13 years who became very stressed about eating, so it was just a question of concentrating on what he was willing and able to eat rather than what was necessarily the healthy option, simply to ensure that he maintained a reasonable weight in the short term.

Is it possible to do any damage to a Heller's myotomy that was performed two years ago through over exercise like sit-ups?

No.

Problems with pills getting stuck in the oesophagus

If the pills are getting stuck in the oesophagus and not reaching the stomach, they are by definition not being absorbed into your system, and not giving you their intended benefit. So blood pressure pills, for instance, would not then be reducing your blood pressure. If you have had an effective myotomy and take your pills standing up, and follow up with a glass of water, and remain upright for a short time afterwards, the pills should reach your stomach and then become absorbed.

Problems with manometry tubes

Sometimes the manometry tube curls round rather than passing through the LOS. It can occasionally relate to level of skill of the operator. Sometimes people need a light sedative if they are unusually tense and anxious about the procedure and this can take place at same time as endoscopy. The modern manometry tubes are much thinner than they used to be. It is still possible to make some good judgements about diagnosis even if the tube does not go down as far as it should; you can still do the challenge swallows and make a good diagnosis with experience even if there is no definitive relaxation pressure reading.

Extreme Cases

There are unusual cases in achalasia where the normal conventional treatments do not work for one reason or another. If there is a short term problem with taking in nutrition, a feeding tube can be used, but this is not really a long term proposition. It is a question of reviewing the treatment to date, whether a myotomy is properly effective, is there intractable reflux, and so on. Eventually, at the very last resort, an oesophagectomy operation can be considered where the oesophagus is removed and the stomach pulled up to be joined to the base of the throat, or the oesophagus replaced with a section of the colon. An oesophagectomy would not be considered simply as an answer for somebody losing weight since weight would be lost as the result of that surgery anyway, and there are a lot of lifestyle considerations involved. When achalasia progresses it is a combination of the oesophagus getting larger and baggier, and the loss of neurons / nerve endings deteriorating rather than just one of these aspects.

What can safely be done about high pressure with the Upper Oesophageal Sphincter as a problem after a Heller's Myotomy and a Dor Wrap fundoplication?

High pressure at the top of the oesophagus is not usually a problem as long as it relaxes to allow the bolus of food to pass through. It might actually be helpful to prevent food from aspirating into the lungs. An ENT specialist would consider dilating the sphincter if appropriate.

Any suggestions for emptying the oesophagus of accumulated saliva and food?

Suggestions included manually pushing up on your stomach to make yourself burp, as if you are 'bringing up wind'. The aim is to go to bed with an oesophagus that is as empty as possible. Drinking warm water first thing in the morning and last thing at night can help. Posture is very important in helping those with achalasia to swallow. Some people stand up, arch their backs, and grip the sides of the table.

How long will a dilatation work for?

The effectiveness of dilatations vary enormously. If it has lasted a year that is quite a good result. If symptoms still persist, you are then looking at a more comprehensive, non-endoscopic intervention.

Can manometry provide the answer why you still have symptoms after a Heller's myotomy?

Yes, manometry and pH acid monitoring can give large amounts of useful data about what might be going wrong if symptoms persist after treatment, so follow-up manometry can be very effective.

The HealthUnlocked forum for exchanging information and tips about achalasia is at <https://healthunlocked.com/achalasia-action>

